

LETTER TO THE EDITOR

Open Access



# The implementation of trauma resuscitation procedures within a field hospital setting in Turkey: an examination of a distinctive collaborative approach

Nihat Mujdat Hokenek<sup>1\*</sup>, Alican Barış<sup>2</sup> and Mehmet Fatih İncelikli<sup>3</sup>

On February 6, 2023, Pazarcık (Kahramanmaraş) and Elbistan (Kahramanmaraş) in Turkey experienced two seismic events, characterized by moment magnitudes (Mw) of 7.7 and 7.6, respectively [1]. Based on authoritative data, the seismic event resulted in a casualty count exceeding 50,000 individuals. Upon the immediate occurrence of the disaster, healthcare professionals nationwide promptly offered their voluntary services to journey to the impacted region.

On the subsequent day following the occurrence of the calamity, a field hospital was promptly established within the premises of the extensively impaired “Hatay Training and Research Hospital” located in Hatay. The individuals who were saved from the debris were transferred via ambulance from the area affected by the catastrophe to the designated medical facility. This correspondence aims to delineate the initial medical procedures conducted on patients who were extricated from the debris at the field hospital.

The organizational structure and task allocation for the red zone of the field hospital were devised by an emergency medicine specialist (EMS). As a result, trauma

teams were established. These teams consisted of four registered nurses, one emergency medicine specialist, and one radiologist. As depicted in Fig. 1, nurses were tasked with the responsibilities of cutting, monitoring patient vital signs, ensuring proper temperature regulation, and establishing intravenous access. During the initial assessment conducted by the Emergency Medical Services (EMS), the radiologist conducted an e-fast examination and Doppler ultrasonography (USG) on the extremities affected by cold exposure. Following that, the radiologist employed ultrasonography to perform the insertion of a central venous catheter. During the initial assessment, EMS communicated the examination results to the secretary, who duly documented them. The individuals who underwent resuscitation and achieved hemodynamic stability were transported via helicopter to a tertiary care facility located in a different city [2].

Due to our methodology, prompt monitoring, rapid warming, and expedited access to intravascular regions were achieved for patients affected by the earthquake. Furthermore, the expeditious nature of the ultrasonographic examination facilitated prompt diagnosis, thereby enabling efficient patient transfers to appropriate medical facilities. Our findings indicate that our methodology can be applicable for conducting primary assessments of patients affected by disasters.

\*Correspondence:

Nihat Mujdat Hokenek  
[nihathokenek@gmail.com](mailto:nihathokenek@gmail.com)

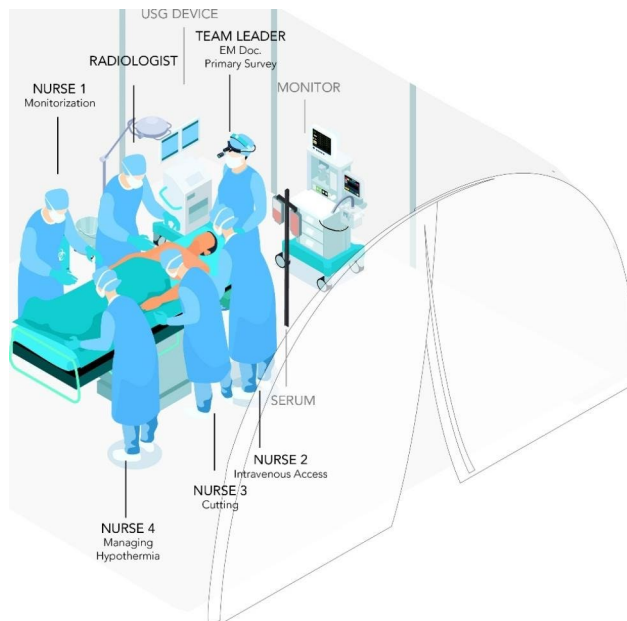
<sup>1</sup>Department of Emergency Medicine, University of Health Sciences, Kartal Dr. Lutfi Kırdar City Hospital, Istanbul, Turkey, Kartal, Turkey

<sup>2</sup>Department of Orthopaedics and Traumatology, University of Health Sciences, Istanbul Physical Therapy And Rehabilitation Training And Research Hospital, Istanbul, Turkey

<sup>3</sup>Department of Radiology, Bursa Uludağ University, School of Medicine, Bursa, Turkey



© The Author(s) 2023. **Open Access** This article is licensed under a Creative Commons Attribution 4.0 International License, which permits use, sharing, adaptation, distribution and reproduction in any medium or format, as long as you give appropriate credit to the original author(s) and the source, provide a link to the Creative Commons licence, and indicate if changes were made. The images or other third party material in this article are included in the article's Creative Commons licence, unless indicated otherwise in a credit line to the material. If material is not included in the article's Creative Commons licence and your intended use is not permitted by statutory regulation or exceeds the permitted use, you will need to obtain permission directly from the copyright holder. To view a copy of this licence, visit <http://creativecommons.org/licenses/by/4.0/>. The Creative Commons Public Domain Dedication waiver (<http://creativecommons.org/publicdomain/zero/1.0/>) applies to the data made available in this article, unless otherwise stated in a credit line to the data.



**Fig. 1** Organization of the trauma team in the field hospital

### Supplementary Information

The online version contains supplementary material available at <https://doi.org/10.1186/s13049-023-01116-7>.

Supplementary Material 1

### Acknowledgements

None.

### Funding

None.

### Declarations

#### Competing interests

None.

Received: 2 September 2023 / Accepted: 4 September 2023

Published online: 28 September 2023

### References

1. <https://depem.afad.gov.tr/press-release-detail/216>.
2. Galvagno SM, Nahmias JT, Young DA. Advanced trauma life support® update 2019: management and applications for adults and special populations. *Anesthesiol Clin*. 2019;37(1):13–32.

### Publisher's Note

Springer Nature remains neutral with regard to jurisdictional claims in published maps and institutional affiliations.